



Durom[®] Femoral Hip Resurfacing Hemi Arthroplasty

Surgical Technique



Transfer force the way nature intended

**Durom Femoral
Hip Resurfacing
Hemi Arthroplasty
Surgical Technique****Table of Contents**

Design Rationale	2
Patient Selection	3
Pre-Operative Planning	4
Surgical Technique	5
Preparation of the Femoral Component	6
Centering Jig	16
Order Information	18

Design Rationale

The *Durom* Femoral Hip Resurfacing Component has been designed for cemented use in patients who are likely to outlive a “conventional” hip prosthesis. Emphasis has been placed on preservation of bone stock and durable fixation of the components to the skeleton.

- The sophisticated femoral instrumentation permits very accurate and reproducible positioning of the femoral component, allowing the smallest possible femoral implant to be used.
- The femoral instruments produce an even cement mantle of approximately 1mm, reducing the risk of fatigue failure of the bone cement. The recesses within the femoral component enhance rotational stability of the implant.



Patient Selection

The *Durom* Hip Resurfacing system femoral component, when used for hemi-hip arthroplasty, has been designed for cemented use in patients who are likely to outlive a conventional hip prosthesis. Femoral hip resurfacing hemi arthroplasty is most appropriate for patients with good bone quality in the femoral head and acetabulum, where the bearing surface and supportive bone structure of the acetabulum is normal, and where acetabular replacement is neither required nor desirable. Such patients will generally be under the age of 65.

Indications

- Noninflammatory degenerative joint disease (NIDJD), e.g., avascular necrosis if remaining bone stock is adequate, and osteoarthritis
- Inflammatory joint disease (IJD), e.g., rheumatoid arthritis
- Joint replacements may be considered for younger patients if any unequivocal indication outweighs the risks associated with the age of the patient and modified demands regarding activity and hip joint loading are assured. This includes severely crippled patients with multiple joint involvement, for whom an immediate need of hip mobility leads to an expectation of significant improvement in the quality of their lives.

Additional indications include other abnormalities where major pathology affects the femoral head; where the bearing surface and supportive bone structure of the acetabulum is normal; and where acetabular replacement is neither required nor desirable.

WARNING: The *Durom* femoral component is not approved for use with the *Durom* Acetabular cup for total hip surface replacement arthroplasty in the USA.

Contraindications

- Acute, chronic local or systemic infections
- Skeletal immaturity
- Severe muscular, neural or vascular diseases that endanger the limbs involved
- Use in patients with bone stock inadequate to support the device including patients with:
 - Severe osteopenia
 - Family history of severe osteoporosis or severe osteopenia
 - Osteonecrosis or avascular necrosis (AVN) with 50% involvement of the femoral head (regardless of FICAT Grade)
 - Multiple cysts of the femoral head (>1cm)

Note: In cases of questionable bone stock, a DEXA scan may be necessary to assess inadequate bone stock.

- Lack of bony structures proximal or distal to the joint, so that good anchorage of the implant is unlikely or impossible
 - Total or partial absence of the muscular or ligamentous apparatus
 - Any concomitant diseases that can jeopardize the functioning and the success of the implant
 - Allergy to the implanted material, above all to metal (e.g., cobalt, chromium, nickel, etc.)
 - Local bone tumors and/or cysts
 - Use in pregnant females or female patients of childbearing age due to the unknown effect of metal ion release
 - Use in patients with known moderate to severe renal insufficiency
- Use in patients with immunocompromised condition, including organ transplant recipient, AIDS, or persons receiving high doses of corticosteroids
 - Patients who are severely overweight (BMI >40)
 - Osteomalacia

Preoperative Planning

Templates are used to determine the approximate size of the appropriate component and to assess potential difficulty because of loss of femoral or acetabular bone stock. Careful pre-operative planning lowers the risk of femoral neck notching. It also assesses the neck shaft angle. This helps to avoid significant varus placement of the femoral component.

Templates are available in 120% magnification for conventional radiographs and 100% magnification for use with digital x-rays (Fig. 1). Magnification is greater in larger patients and less in thinner patients. The final determination of the prosthesis size is therefore made at the time of surgery.

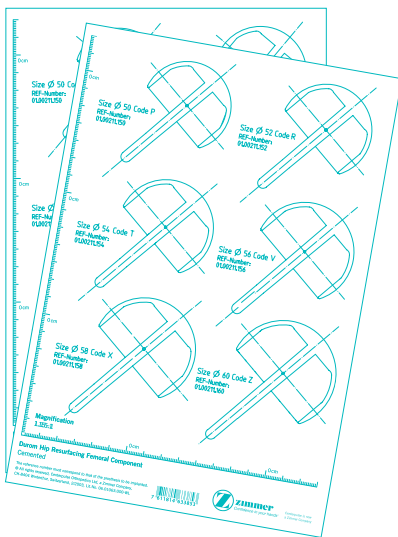
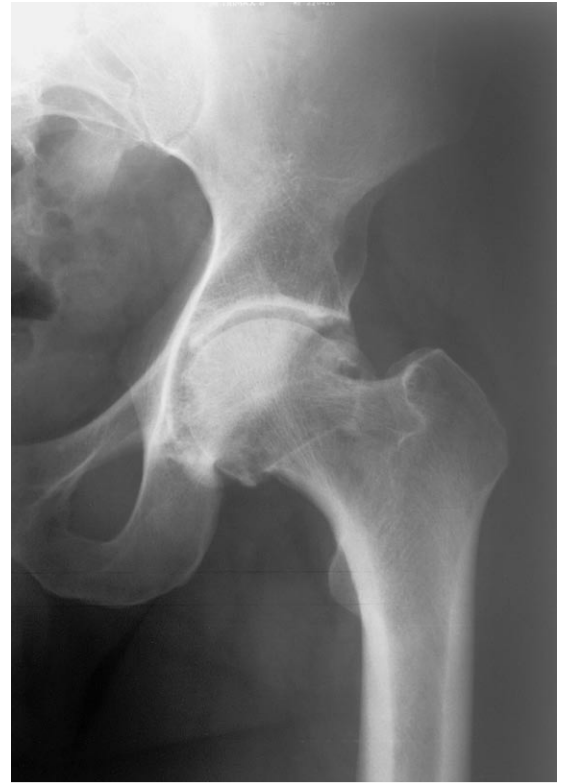

Fig. 1 Planning Template

Surgical Technique

The authors recommend a posterior approach to the hip. This approach provides good exposure without disruption of the abductor muscles. Preservation of abductor muscles ensures normal hip function and may be important in reducing the risk of femoral neck fractures following hip resurfacing. Femoral hip resurfacing can also be carried out through a direct lateral approach without difficulty.

The authors would not recommend the routine use of a formal trochanteric osteotomy, as this can potentially diminish the blood supply to the femoral head.

The details of the operative technique are based on a posterior approach to the hip.

Surgical Approach

- 1 A standard posterior approach is used with the patient in the lateral position. In obese patients care must be taken to ensure that the incision of the limb extends sufficiently posteriorly to allow adequate access to the femoral head and neck later in the procedure. Following longitudinal incision of the fascia lata and splitting of the fibres of gluteus maximus, the tendinous insertion of the gluteus maximus into the linea aspera is exposed. The tendinous insertion should be fully released from the femur. This will allow easier displacement of the femoral head antero-superiorly during acetabular assessment.
- 2 A posterior capsular flap incision is used releasing fully the short external rotators, including the whole of quadratus femoris and the posterior joint capsule. The undersurface of gluteus minimus is elevated off the roof of the acetabulum as far anteriorly as the anterior rim. The superior capsule is divided along the superior rim of the acetabulum.
- 3 The hip is dislocated and the circumferential capsulotomy is completed. The antero-inferior capsule can be most easily accessed by maximal internal rotation of the femur with the hip extended. The capsule should be divided in line with the psoas tendon. The antero-superior capsule is best accessed by maximal internal rotation of the femur with the hip in flexion.
- 4 The head-neck junction is cleared of soft tissue and any significant osteophytes around the femoral neck are carefully removed. The removal/preservation of femoral neck osteophytes is a balance between femoral oversizing, impingement and potential weakening of the femoral neck. "Soft" osteophytes, commonly found along the anterior neck, can be removed if they cause impingement in flexion. This procedure reduces the risk of notching. "Mature" corticated osteophytes, commonly found along the superior (lateral) and inferior (medial) neck should be preserved if at all possible and the femoral component translated accordingly. In order to avoid oversizing, such mature osteophytes can be cut into, but only to the level of the head-neck junction. Mature osteophytes down the neck should not be removed. The diameter of the femoral neck in its widest plane (usually superior-inferior) is measured using the callipers. This will determine the smallest femoral component that can be used without the risk of notching of the femoral neck.
- 5 The femoral head is manipulated under the fibres of gluteus minimus to lie superior to the acetabulum. Care must be taken not to damage the fibres of gluteus minimus during this maneuver. Using a T-handle bone hook, the femoral head and neck are then translated anteriorly so that the head comes to light close to the anterior inferior iliac spine under the hip abductors.
- 6 In a case with a marked fixed external rotation contracture, the contralateral hip can be used to assess the true neck-shaft angle.

Preparation of the Femoral Component

The femoral head and neck are most easily accessed by maximal internal rotation of the femur with the hip flexed to 90 degrees. The femoral head can be delivered out of the wound using the femoral head elevator. An adequate surgical exposure reduces the risk of femoral neck notching.

To reduce the risk of post operative femoral neck fracture, it is imperative that the femoral neck is not notched during preparation. Reaming is based on the center of the femoral neck, not the center of the femoral head, which, due to remodelling, is often eccentrically located on the femoral neck.

Insertion of the guide wire

A guide wire is inserted to a depth of approximately 5cm in line with the midpoint of the femoral neck in both planes. The protractor can be used to help set the neck-shaft angle (usually 135 degrees) (Fig. 2). Anteversion is most appropriately based on the antero-inferior cortex of the femoral neck viewed from below (Fig. 3).

The guide wire does not determine the final position of the femoral component. However, it should be placed as accurately as possible to facilitate the later stages of the procedure.

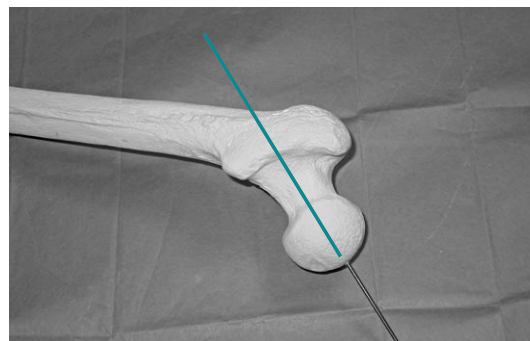


Fig. 2

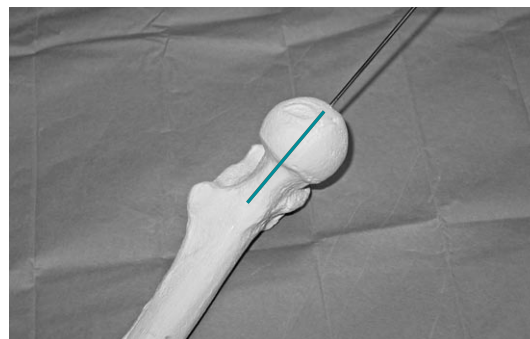


Fig. 3

In primary osteoarthritis the anterior and superior quadrants of the femoral head are usually deficient. It is therefore usually the case that the guide wire appears to be placed eccentrically on the femoral head in a superior and anterior direction. In cases of slipped upper femoral epiphysis this apparent eccentric placement of the guide wire can be extreme.

Femoral head planing

The plane cutter is passed over the short guide wire and a flat surface on the femoral head is prepared (Figs. 4 & 5). The dome of the femoral component is 9mm thick. However, at this stage it is advisable to remove only approximately 6mm of bone, leaving behind some bone for final preparation of the femoral head later in the procedure.

Attachment of the base plate

The base plate is available in two sizes. The standard base plate can be used on most femoral heads. The small base plate may need to be used when the femoral neck diameter is less than 46mm. The base plate size is not linked definitively to the implant size.

The base plate is attached to the base plate impactor/extractor and hammered on to the prepared flat surface of the femoral head (Fig. 6). The base plate should be orientated so that the laser-etched markings are positioned anteriorly and posteriorly (Fig. 7).

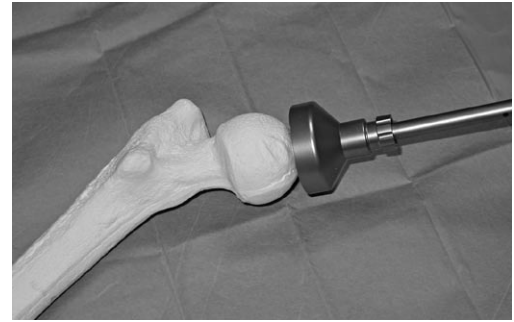


Fig. 4

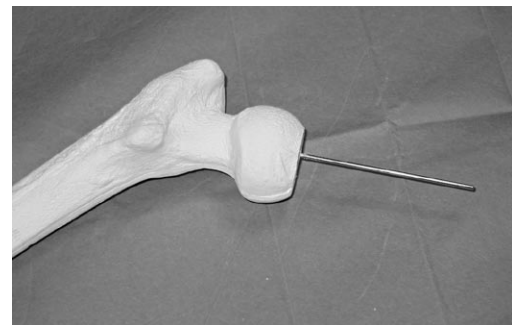


Fig. 5

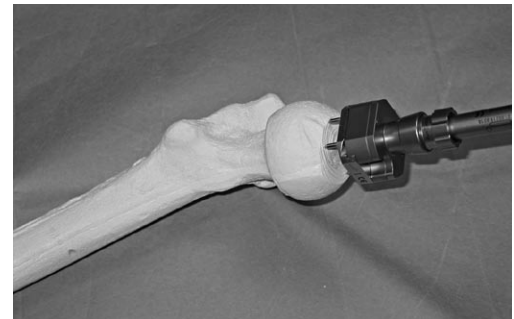


Fig. 6

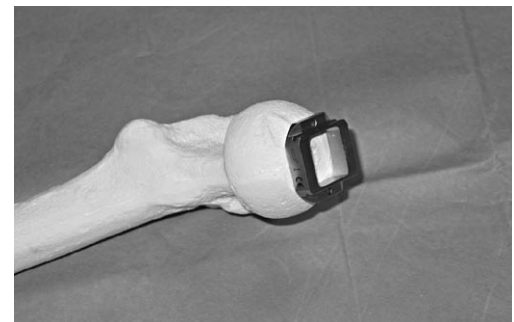


Fig. 7

Attachment of the centering jig

The assembled centering jig is slid on to the base plate (Fig. 8). The large locking ring is tightened to control anterior/posterior and superior/inferior movement. The small locking ring is tightened to independently control movement of the cannulated rod in all planes. Correct use of the precision femoral jig to avoid excessive valgus ($>5^\circ$ compared to neck-shaft angle), anteversion or retroversion and to adopt the appropriate medio-lateral and antero-posterior translation. The use of the jig and appropriate stylus will help minimize the risk of notching the femoral neck. The objective is to obtain a stem-shaft angle between neutral and 5° valgus of the neck-shaft angle.

The *Durom* system offers 3 ways to achieve the appropriate angular alignment:

- The guide rod of the femoral jig is aligned with the long protractor (which overlies the femoral shaft and neck), set to the pre-determined neck-shaft angle from pre-operative templating.
- The antennae apparatus is used to align the guide rod of the femoral jig with the patient's femoral neck.
- The antennae apparatus is used to align the guide rod of the femoral jig with a point on the lateral femoral cortex a pre-determined distance from the tip of the greater trochanter, based on pre-operative templating.

In practice, a combination of these techniques is used to obtain the appropriate angular alignment.

Setting the neck-shaft angle and anteversion angle

The small locking ring is loosened to allow the cannulated rod to be moved to set the definitive neck-shaft angle and anteversion angle. The same technique is used as for the provisional short guide wire. Once the appropriate position has been achieved the small locking ring is tightened with the small tightening bar to lock the cannulated rod in position. The antennae apparatus can then be slid over the cannulated rod to verify that the correct neck-shaft angle and anteversion angle have been achieved (Figs. 9, 10 & 11).




Fig. 8

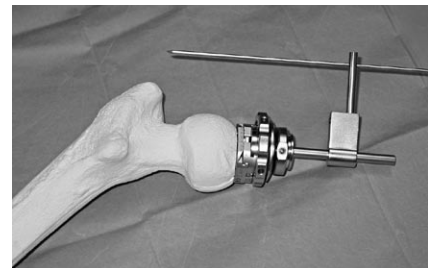


Fig. 9

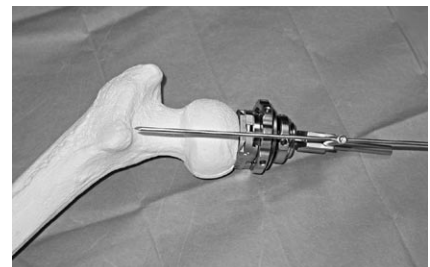


Fig. 10

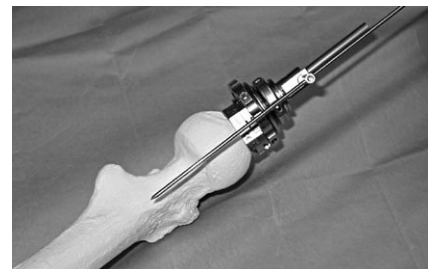

Fig. 11

Adjusting the centering jig

The large tightening ring is loosened. When the ring is fully loose the jig can be moved in both the anterior/posterior and superior/inferior directions. When the ring is partially tightened, movement in the anterior/posterior direction is lost first. It is therefore possible to precisely position the jig sequentially.

The stylus corresponding to the previously measured diameter of the femoral neck is attached to the cannulated rod using the connector. The tip of the stylus is then positioned with appropriate clearance of the posterior cortex at the level of the head and neck junction (Fig. 12). The large tightening ring is partially tightened to lock the stylus in place in the antero-posterior direction.

The stylus is then rotated around to the superior and inferior cortex at the level of head-neck junction and its position adjusted to ensure adequate clearance around the superior and inferior neck (Fig. 13). The large tightening ring is then fully tightened, locking the jig in place. With the jig fully locked it is easy to rotate the stylus around the anterior head-neck junction to ensure appropriate clearance. If necessary, the large tightening ring can be loosened and the jig repositioned.

The stylus is then placed on the femoral head and rotated to demonstrate where the head will be cut and the consequent support for the femoral component (Fig. 14).

The anterior and superior quadrants of the femoral head are usually deficient in primary osteoarthritis. It is therefore advisable to position the jig as much posteriorly and inferiorly as possible without notching the femoral neck. This will maximize the support for the femoral component.

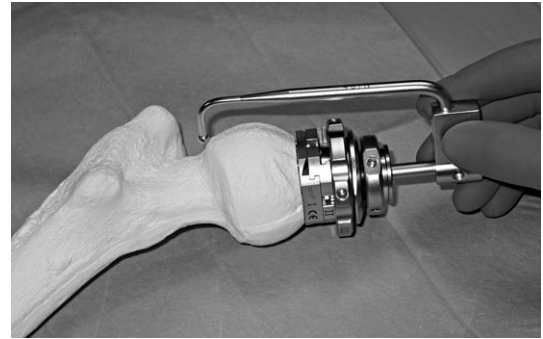


Fig. 12

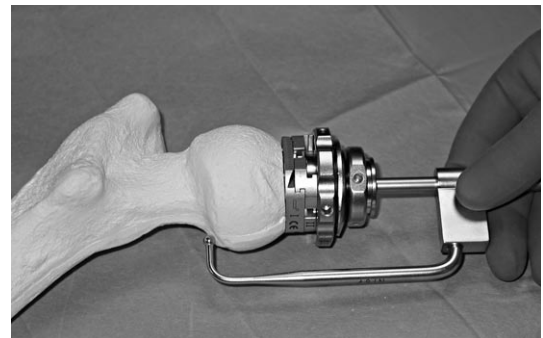


Fig. 13

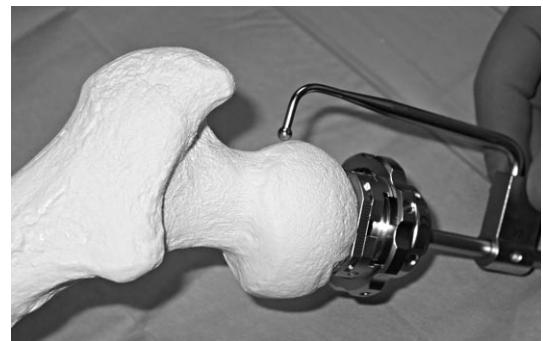

Fig. 14

Insertion of the definitive guide wire

A wire is inserted into the cannulated rod and drilled down the femoral neck until it abuts the lateral cortex of the proximal femur (Fig. 15). The centering jig, with the base plate, is then removed from the femoral head with the base-plate impactor/extractor (Fig. 16).

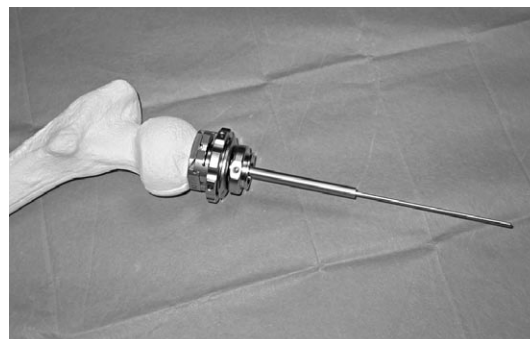


Fig. 15



Fig. 16

Insertion of guide rod

The guide wire is overdrilled to the appropriate depth for the chosen implant based on the markings on the drill (Fig. 17). The guide wire is removed with the wire extractor provided. The guide rod is then inserted (Fig. 18).

Placement lower than 130° should be avoided. Therefore check with the protractor if the angle of the guide rod is higher than 130° .



Fig. 17

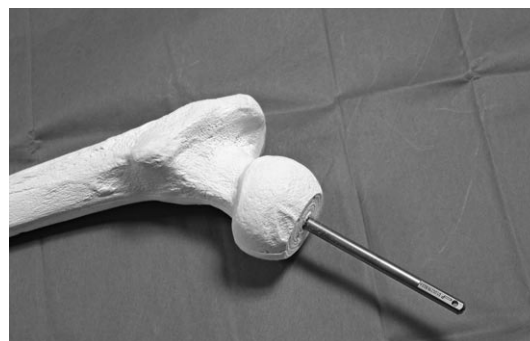

Fig. 18

Cylinder reaming

The femoral head is prepared first with cylinder cutters, one or two sizes larger than the chosen implant (Fig. 19). Careful, sequential femoral reaming, commencing with a reamer 2-4mm larger than the templated size. Stop cylinder reaming at the head-neck junction, to avoid damage to the lateral (superior) cortex of the femoral neck (Fig. 20). The cylinder cutter has a depth stop, but care must be taken when approaching the head-neck junction to avoid notching. Because an eccentric amount of the peripheral femoral head is removed, it may be necessary to complete the posterior-inferior cut with an osteotome. Any remaining peripheral bone and femoral neck osteophytes can then be removed with a rongeur.

The cylinder cutter corresponding to the chosen implant size is then used to recut the femoral head to the definitive size. Again, care should be taken when approaching the head-neck junction to ensure that notching of the femoral neck does not occur.

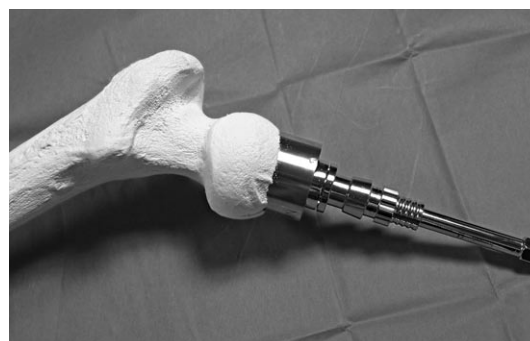

Fig. 19

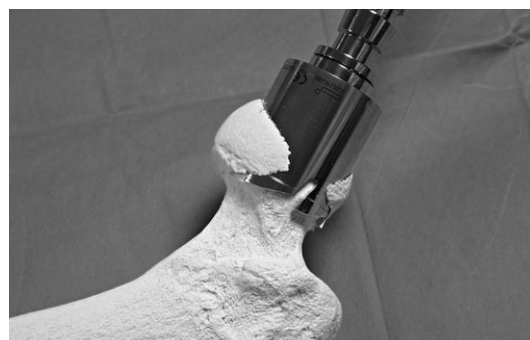

Fig. 20

Definitive head planing

The depth markings on the calliper can be used to determine the appropriate positioning of the femoral component on the head (Fig. 21). In general, the mouth of the femoral component should be at the level of the head-neck junction. The appropriate depth is marked on the femoral head and the head recut to the correct depth using the femoral head planer over the guide rod (Figs. 22 & 23). Often, very little bone is removed at this stage (2–3mm).

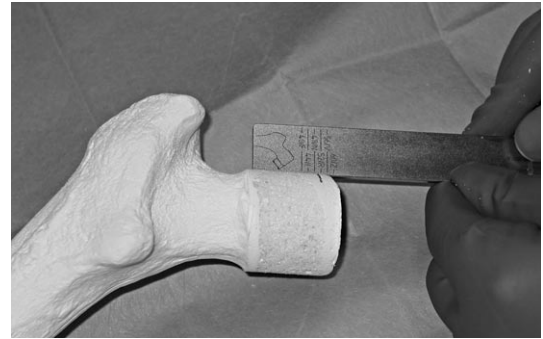

Fig. 21

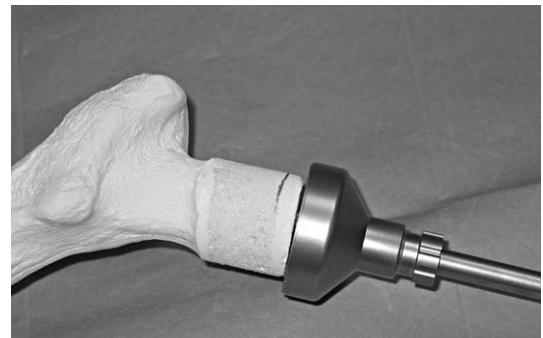


Fig. 22

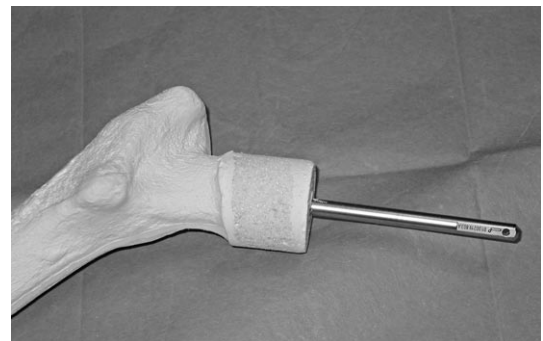


Fig. 23

Chamfer cut

The chamfer is cut with the appropriate sized chamfer cutter over the guide rod (Figs. 24 & 25).

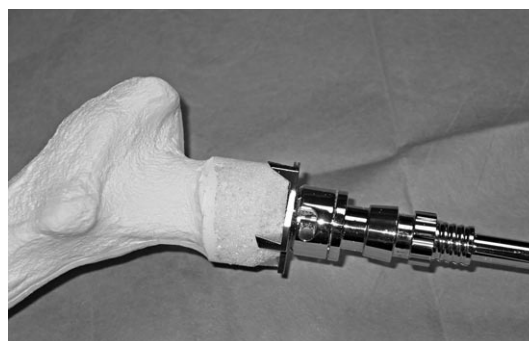


Fig. 24

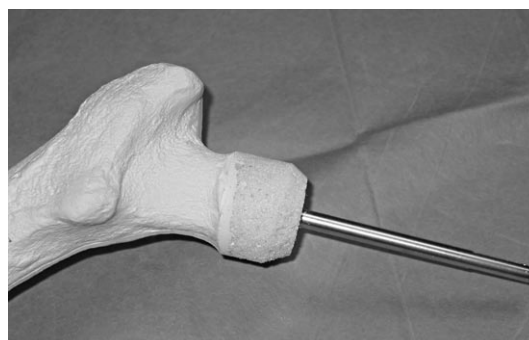


Fig. 25

Femoral trial

The appropriate femoral trial is advanced over the guide rod (Fig. 26). The cement mantle is built into the femoral trial which should therefore be a relatively tight fit. The support for the femoral component can be assessed through the window in the femoral trial. The position of the mouth of the femoral trial is marked on the femoral head with a marker pen or diathermy.

The guide rod is removed using the guide-rod extractor.

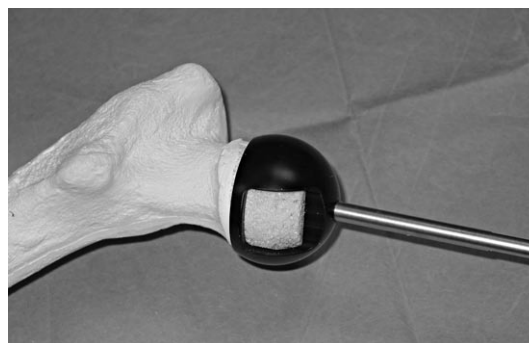

Fig. 26

Final preparation of the femoral head

Cement keyholes are prepared in areas of sclerotic bone of the femoral head using a guarded drill. Cysts in the femoral head should be curetted clear of soft tissue. Large cysts can be grafted. Small cysts can be used as cement keyholes.

The femoral head is then cleaned using pulsed lavage. A sucker can be inserted into the guide-rod hole just prior to cementation to ensure that the femoral head is free from blood.

Cementation

The femoral component is filled with low viscosity bone cement to approximately the level of the internal recesses. If there are large defects in the femoral head, more bone cement may be required.

The slim femoral stem is an alignment device, which helps to maintain an even cement mantle. The stem is not designed to transmit force. It is undersized compared to the pre-drilled hole. Cement should not therefore be placed around the stem or down the guide-rod hole.

The recesses around the mouth of the implant allow egress of cement and controlled pressurization. The femoral component should therefore be introduced on to the prepared femoral head when the cement is at the early doughy stage (the time to reach the doughy stage of the cement is dependent upon operating-room temperature, cement storage-conditions, etc. and may vary between different cements). The femoral component is seated on to the femoral head manually or using the femoral pusher (Fig. 27). Forceful impaction should not be required to fully seat the component, as excess cement can escape under pressure through the cement recesses. All extruded cement around the periphery of the femoral component is removed. The femoral head and neck are thoroughly cleaned with pulsed lavage and wet swabs. The cement is allowed to cure fully before reduction (Fig. 28).

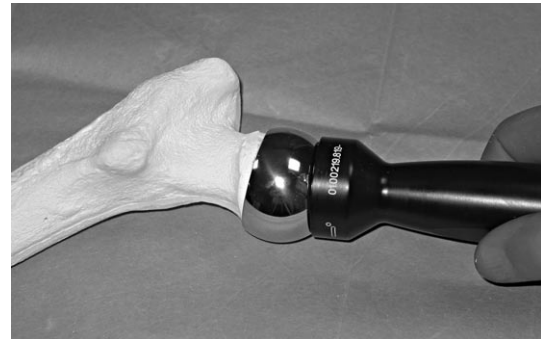

Fig. 27

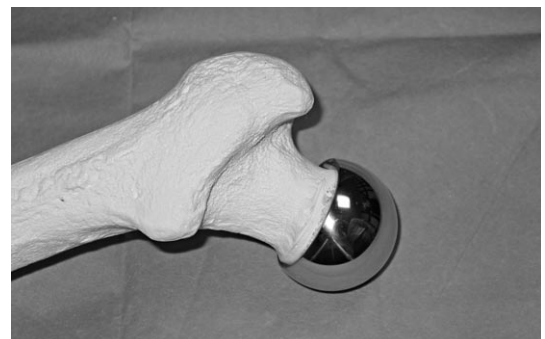

Fig. 28

Reduction

The acetabulum is exposed by retraction of the posterior capsular flap. The assistant then reduces the femoral component by longitudinal traction and external rotation of the leg. Following reduction the circumference of the acetabulum is checked to make sure there is no entrapment of soft tissue. The hip is then checked for range of movement and stability.

Closure

The capsule and short external rotators are meticulously repaired to the posterior edge of the greater trochanter. The wound is then closed in layers.

Aftercare

Patients are generally mobilized the day after surgery, with light partial weight bearing on their operated leg. Progression to full-weight bearing is dependent on the individual surgeon's protocol, but need not be different from stemmed hybrid hip replacements.

Centering Jig

Malpositioning of the femoral component was one of the frequent failure modes with early-generation resurfacing solution. Accurate positioning focused on the axes of the femoral neck and therefore optimal positioning of the implant is the ultimate goal of the instrument development in cooperation with experienced resurfacing consultants. The centering jig is a novel solution which offers the possibility of precise positioning with visual control options.

Part Description



I. base plate small & large



II. connection slide



III. large locking ring



IV. oval ring



V. cannulated rod



VI. small locking ring




base plate holder (auxiliary)

Assembling Guide

- 1** Place the base plate (I) into the black base plate holder.

1



- 2** Insert the connection slide (II) into the base plate (I).

2



- a** Assemble the oval ring (IV) and the large locking ring (III) by turning the large locking ring counter clockwise on to the oval ring (IV).



- b** Mount the assembled part on the connection slide (II).



a

b

- 3** Set the cannulated rod (V) into the top opening of the oval ring (IV) and secure it by screwing the small locking ring (VI) clockwise into the oval ring.

3



Disassembly and Cleaning

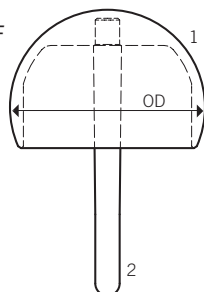
The centering jig needs to be completely disassembled for cleaning purposes. Unlock all rings and sliding devices. Remove residual tissues or blood and clean each of the six parts of the centering jig separately. After sterilization store the parts disassembled.

Order Information



Durom Femoral Component

- 1 Protasul[®]-21 alloy WF
- 2 Protasul-20 alloy cemented



STERILE R

Size = OD*-mm	Code	REF
38	D	01.00211.138
40	F	01.00211.140
42	H	01.00211.142
44	J	01.00211.144
46	L	01.00211.146
48	N	01.00211.148
50	P	01.00211.150
52	R	01.00211.152
54	T	01.00211.154
56	V	01.00211.156
58	X	01.00211.158
60	Z	01.00211.160

* OD = Outer Diameter

** ID = Inner Diameter

Please refer to package insert for complete product information, including contraindications, warnings, precautions, and adverse effects.

Contact your Zimmer representative or visit us at www.zimmer.com

